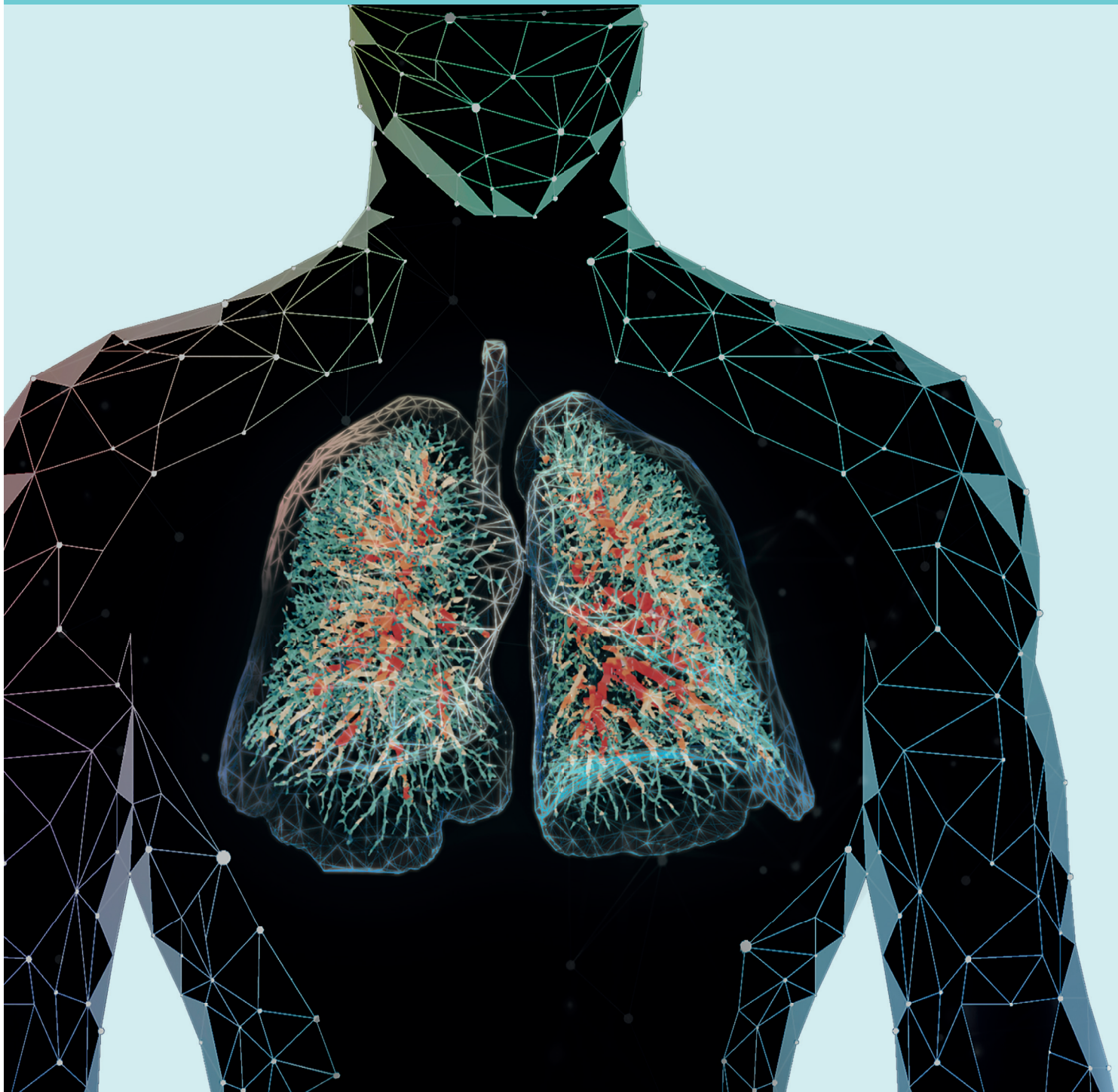
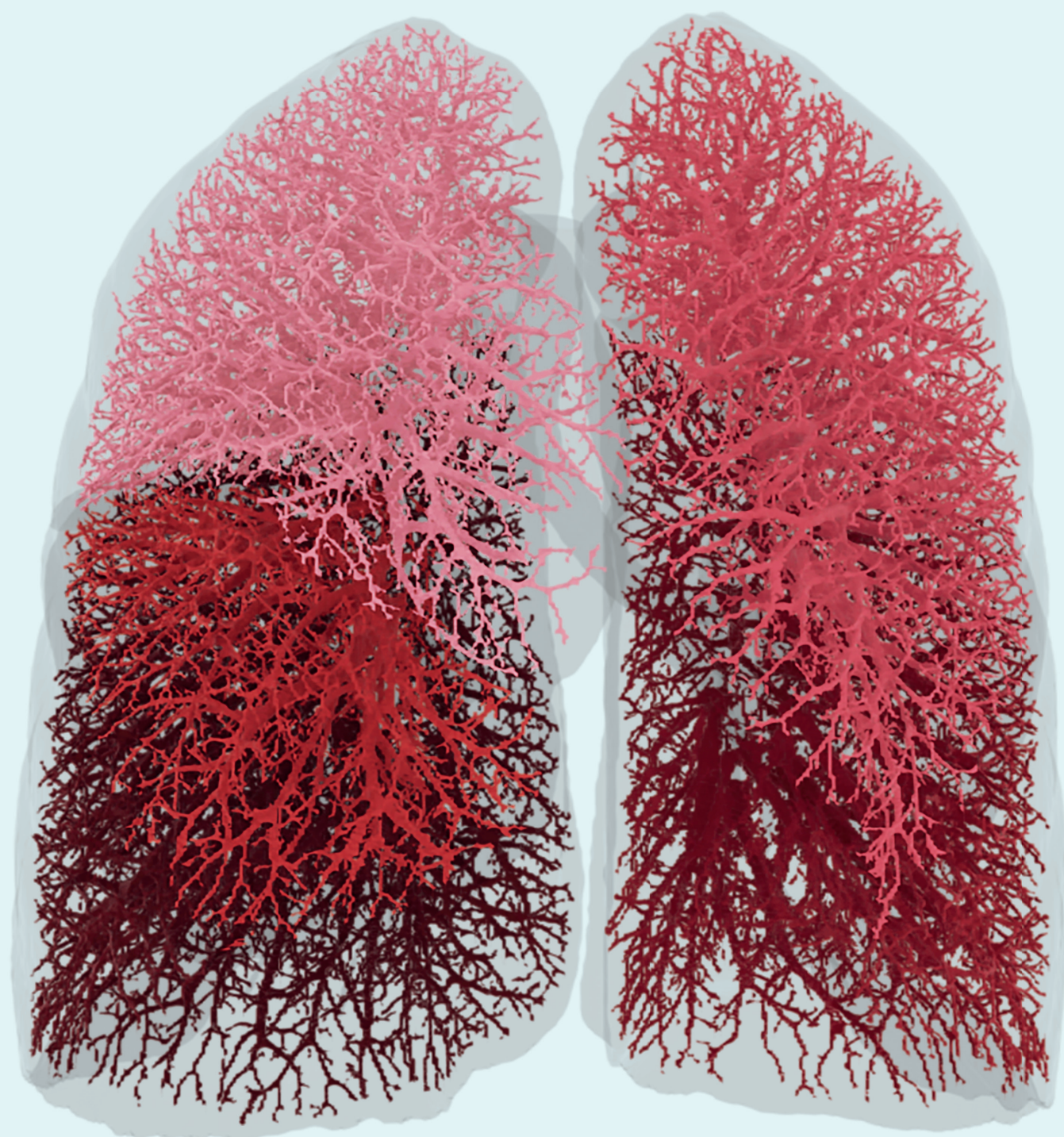


## In this Issue

- FRI as a solution for unmet patient needs
- Recent data on COVID-19 and COPD
- Make clinical trials smaller,  
faster and more cost efficient







4

## Functional Respiratory Imaging: an innovation at just the right time

Interview with:  
**Dr. Jan De Backer**  
**Prof. Dr. Wilfried De Backer**



8

## The need to measure

Interview with:  
**Prof. dr. David Langton**



11

## FRI adds an important dimension to conventional imaging techniques

Interview with:  
**Dr. Muhunthan Thillai**



14

## The advent, value and place of quantitative imaging

Interview with:  
**Dr. Firdaus Mohamed Hoesein**



17

## FRI Publications - Papers

Dear reader,

We are proud to present the first edition of the Fluidda Magazine on FRI technology.

Imaging has played an increasingly important role in the diagnosis and treatment of pulmonary disease in recent years. Unlike traditional measures of lung health, imaging provides important regional information about the condition of the lung. The sensitivity of imaging endpoints has facilitated smaller, shorter clinical trials. Meanwhile, advances in CT technology have allowed for high resolution scans with progressively lower radiation exposures, removing yet another barrier to widespread use. Functional Respiratory Imaging (FRI) technology, developed in house by Fluidda, combines quantitative analysis of CT scans with the techniques of computational fluid dynamics (CFD) to provide unique insight into both the structure and the function of a patient's lungs.

With FRI, clinical research into new drugs and treatment methods can often be performed faster, more cost-effectively, and with fewer patients in all stages of development.

Recently, FRI technology has provided important data in the fight against COVID-19, leading to a number of publications in high-impact journals.

With the recent FDA approval of FRI as a medical device for use in clinical practice, FRI can now be used by HCPs in clinical to assist in diagnostics, treatment selection, and patient monitoring. In this issue of Fluidda Magazine, a number of users of FRI technology explain what its added value has been for their research, and Fluidda founders Prof. Wilfried and Dr Jan De Backer explain what drove them to develop this technology. We hope these interviews will provide you with inspiration for your future projects, and wish you happy reading!

On behalf of Fluidda,

**Huib Koets**  
 International Marketing Manager

### Colofon

**Volume 1, issue 1**  
 The Fluidda Magazine on  
 Functional Respiratory Imaging  
 is a publication of iDoctor B.V.

**Fluidda/FRI-technology:**  
 Fluidda N.V.  
 Groeningenlei 132  
 2550 Kontich  
 Belgium  
 info@fluidda.com

**Publisher:**  
 iDoctor B.V.  
 Sleepboot 9a  
 3991 CN Houten  
 The Netherlands  
 staff@idoctornet.com

**Coordination and editing:**  
 Huib Koets &  
 Lynette Wijgengangs

**Production:**  
 Badoux printing house,  
 Houten, the Netherlands  
 Print edition: 1000 copies.

**Design:**  
 Michèle Duquesnoy &  
 Louis Vissers

**Images:**  
 Fluidda

### © 2021

It is not permitted without prior permission from iDoctor B.V. to copy articles, graphics or pictures as well as parts thereof and publish or distribute them in the broadest sense of the word. Anyone who believes that they should derive any claims from texts and images included in this publication must contact the publisher.





Author: Patrick Marx

# Functional Respiratory Imaging: an innovation at just the right time

## **PROF. DR. WILFRIED DE BACKER** **EXECUTIVE CHAIR BOD FLUIDDA**

Wilfried De Backer has built his academic career at the University of Antwerp where he finished his affiliation as full professor of Respiratory Medicine in 2017. He obtained his PhD in 1988 with a thesis on the Chemical Regulation of Breathing in men. Starting from this basis, he mainly studied the pathogenesis of sleep related breathing disorders. The focus of his research has always been on pathophysiology of respiratory disease. In the same spirit he encouraged the development of a new functional respiratory imaging technique FRI, that helps to understand the functional behaviour of the upper and lower airways. Phenotyping of patients with FRI belongs to his ongoing clinical research topics. Related to his clinical and research interests, he founded within the European Respiratory Society (ERS) the scientific group on Sleep as part of the Clinical Physiology Assembly. Later, as chair of the Assembly, he reoriented the Assembly with respect for its pathophysiological origin towards several new domains including functional imaging and pulmonary vascular diseases. He published over 250 peer reviewed papers, (H Index of 44). At present his clinical focus is on patients with respiratory insufficiency that are seen in the framework of pulmonary rehabilitation.

## **JAN DE BACKER, PHD, MBA** **CEO FLUIDDA**

Jan De Backer graduated from Delft University of Technology, The Netherlands as aerospace engineer. He attained an MSc degree in aerodynamics and specialized in applied biomedical computational fluid dynamics leading to a PhD from the University of Antwerp, Belgium. He is an alumnus of the MBA programs at London Business School, London and Columbia Business School, New York. Dr. De Backer has received several awards for his innovative research in the field of airway modeling in respiratory and sleep medicine. His work has been published in international journals. Dr. De Backer founded FLUIDDA in 2005 and he has held the position of Chief Executive Officer since 2007.



Every patient deserves to receive the treatment they need. In pulmonology, however, where it is becoming increasingly clear that diseases such as asthma and COPD have many phenotypes, it is difficult to prescribe individualized treatments. The gold standard for diagnosis, spirometry, is unable to differentiate between pulmonary disease phenotypes, but Functional Respiratory Imaging does have that ability. It is a technique that makes better follow-up of diagnostics and treatment selection possible.

‘COVID-19 has made the demand for innovative diagnostic techniques greater than ever. We are having difficulty bringing the pandemic under control, partly because the tools we use to detect and treat the disease are not sufficiently responsive to the situation. Hence there is a substantial need for innovation in the respiratory field’, says Dr Jan De Backer, CEO of Fluidda. De Backer developed Functional Respiratory Imaging (FRI) in collaboration with his father, Dr Wilfried De Backer, Emeritus Professor of Respiratory Medicine at the University of Antwerp. FRI shows the anatomy of the airways and blood vessels in the lungs and the flow of air through them at millimetre-level resolution.

#### QUANTITATIVE TECHNIQUE

A radiologist will examine a CT scan of the lungs purely by eye and then describe it, with the result that only larger abnormalities and abnormal patterns are detected. ‘It is very difficult even for a practised eye to see small abnormalities or create a three-dimensional reconstruction of the lungs in the mind’s eye. With our technique we can do that’, continues Jan De Backer.

‘FRI is a quantitative technique that produces a 3D map of all the clinically relevant structures in the lungs, such as the alveoli, blood vessels and lung volume, using images from a standard CT

scanner’, says Jan De Backer. FRI even shows small abnormalities. The technique developed by the De Backers is able to show diffuse disease-related changes at very high resolution and monitor the changes over time. FRI thus enhances a radiologist’s performance, and outperforms spirometry, which at present is still the gold standard for analysing lung function.

FRI analysis starts with two CT scans, the first after deep inspiration and the second after normal expiration. The patient uses a mouthpiece that records his or her breathing to enable the scans to be timed correctly. After that, the work of the hospital and the patient is done. The two scans are sent to Fluidda in the Belgian village of Kontich, only walking distance from the university hospital in Antwerp. Jan De Backer: ‘Our systems are based on machine learning and artificial intelligence. Every CT scan that we analyse improves our algorithms. We analyse and model the images using computational fluid dynamics, a flow simulation system that has its origins in the aerospace industry. That yields a three-dimensional image of the lungs, showing the flow of air and revealing areas of increased air resistance or places where inhaled particles have been deposited.’

#### ONE MILLIMETRE

Jan De Backer gives an example of just how sensitive the technique is. ‘Pulmonary hypertension can be due to constriction of the smallest blood vessels in the lungs. This causes the blood to accumulate in the feeder blood vessels, which expand slightly. We can see the expansion even in blood vessels with a diameter of only one millimetre. That makes FRI a very patient-friendly option for diagnosing and monitoring pulmonary hypertension, which at present is done using invasive pressure measurement in the pulmonary artery.’ Using FRI, scientists have discovered that thrombosis in small blood vessels plays a major role in severe COVID-19. The finding made using FRI has now been confirmed by autopsies (see the interview with Muhunthan Thillai).

Like the field of computational fluid dynamics (CFD), Jan de Backer also comes from a background in aerospace. De Backer first encountered CFD while studying aerospace engineering at Delft University of Technology in the Netherlands. It was his father, Wilfried De Backer, who then hit on the idea of using the technique to model the flow of air through the lungs. The big challenge for the Fluidda researchers was to adapt the computer technology to use lung data – after all, a lung is rather different from the smooth surface of an aircraft. Jan De Backer: ‘A lung – especially a diseased lung – has an irregular structure. You need to set the right boundary conditions to map flow in the lungs using computational fluid dynamics. We managed to obtain those boundary conditions directly from the CT scans, so that each measurement is individual.’ Wilfried De Backer adds: ‘FRI yields an accurate, personal representation of the anatomy of the airways and blood vessels in the lungs and the flow of air through them, so it is not based on a general model.’

Several completed and current phase 1-4 clinical trials of drugs for pulmonary disease owe their success (or potential future success) to the Fluidda technique.

## GOLD STANDARD

The motivation for developing FRI was EUROSCOPE (European Respiratory Society Study on Chronic Obstructive Pulmonary Disease), a study conducted in the 1990s to explore the effects of inhaled corticosteroids on COPD. Wilfried De Backer: 'In order to reach a worthwhile conclusion, we had to monitor 1,200 patients over three years. Although the study produced significant results, it gave rise to lengthy discussions among respiratory physicians on the value of inhaled corticosteroids for treating COPD. The EUROSCOPE study set me thinking about an alternative to spirometry. My son Jan then told me about computational fluid dynamics, and I thought we could obtain the requisite information from CT scans. We started developing FRI in 2005, and thanks to huge progress in computer technology and artificial intelligence we've managed to develop a technique that works well.'

At present, GPs and respiratory physicians diagnose lung diseases based on symptoms, blood tests, and usually spirometry. Jan De Backer: 'The treatment for most pulmonary diseases is the same for a substantial majority of patients, who are given medication via an inhaler, for instance. Spirometry is then used to check whether their lung function has improved. Spirometry is the gold standard, but it only gives a general idea of lung function, whereas FRI gives a detailed, personalised picture.' Pulmonologist Wilfried De Backer adds: 'Take people with end-stage COPD, for example: they all have an FEV1 of 25%, but they're not all the same. If you treat a patient based on that one FEV1 value, the treatment is not really targeted, as you have no information on the pathophysiology in the lungs. FRI provides pathophysiological information on such things as blood vessels, pulmonary hypertension and the sites of resistance in the distal alveoli.'

**FRI yields an accurate, personal representation of the anatomy of the lungs and the flow of air and blood in them, so it is not based on a general model.**

## BRONCHOLAB

The FDA approved Functional Respiratory Imaging as a diagnostic tool, under the name of Broncholab, in 2020. Jan De Backer: 'We expect to receive European approval in the first quarter of 2021. It is not Fluidda's aim to test all patients using FRI immediately. Most patients respond well to the treatment they receive from their GP or respiratory physician, and for them spirometry is adequate to analyse their lung function. We are focusing initially on patients whose treatment options have currently been exhausted: the question is whether the respiratory physician can find out, using FRI, whether there are reasons for the failure of their treatment. FRI also lends itself to predicting clinical outcomes. In COVID-19, for instance, we find that vascular problems in the lungs detected using FRI are predictive of a poorer clinical outcome. The physician can then opt for more aggressive treatment, based on the FRI information.'

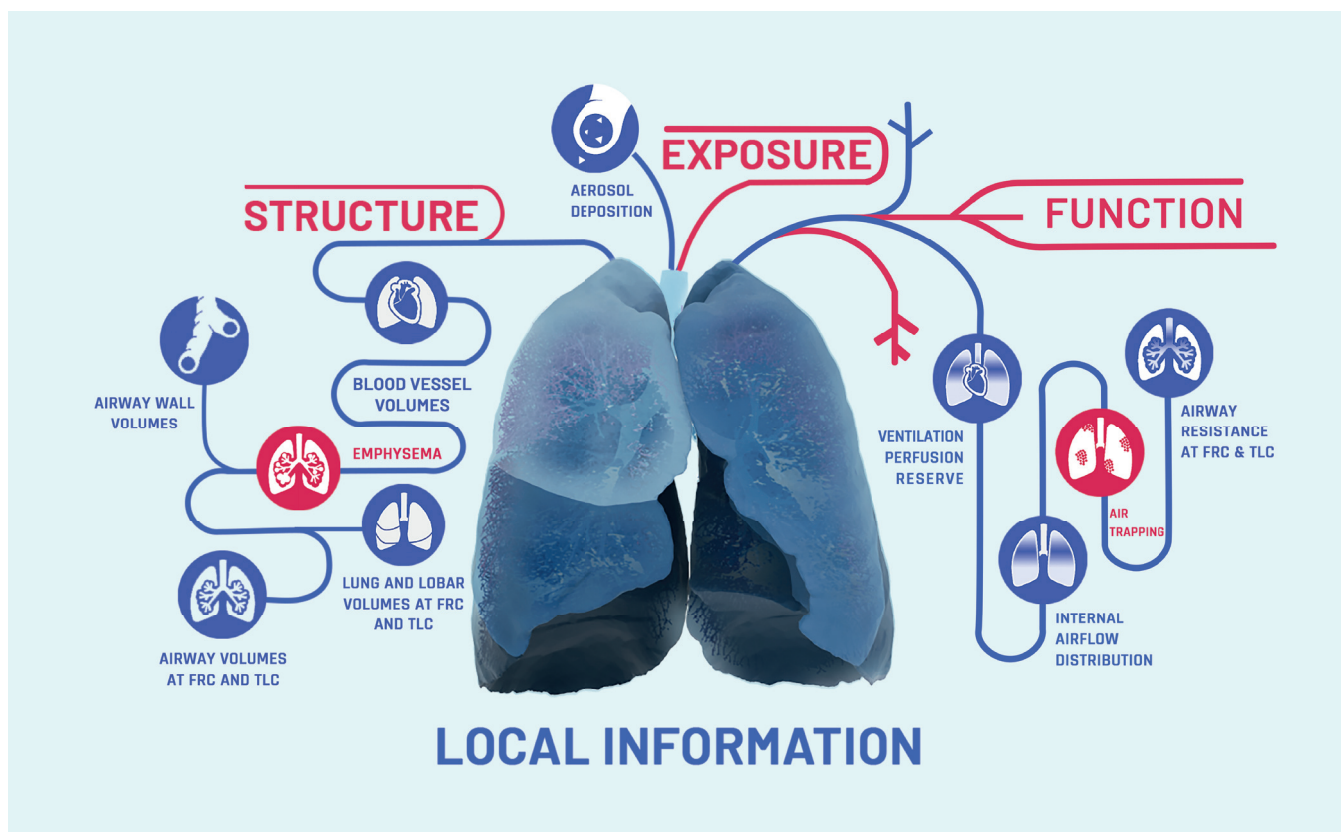
Wilfried De Backer goes on: 'With FRI we can see sooner whether treatment goals are being met. At present it can take a year for treatment using biologics to produce an improvement in the FEV1 in patients with pulmonary disease. With FRI we can see after only one or two months whether there are improvements in geometry and/or function that spirometry does not detect. This has the advantage that we can review expensive treatments quickly and discontinue them if necessary, thus avoiding unnecessary adverse effects on patients and saving on the high cost of biologics.'

## COST SAVINGS

As for the cost savings from FRI, Jan De Backer says: 'Cardiac catheterisation to diagnose pulmonary hypertension costs between five and twenty thousand dollars in the USA. An FRI scan costs only a few hundred dollars. COPD exacerbations in the USA cost over ten billion dollars a year. We know that a substantial proportion of those people are struggling with a treatable but undiagnosed vascular problem in the lungs. With FRI it can be diagnosed. If the treatment prevents 10% of exacerbations, that already yields a billion dollars in savings.'

FRI is proving its value not only in patient care but also in pharmaceutical research. Wilfried De Backer's personal experience again comes into play: 'As a member of the European Medicines Agency, I noticed that a lot of products were failing to be approved because there was insufficient evidence of their efficacy based on spirometry, while there was indirect evidence that they worked. There was huge frustration about the fact that we were missing a lot of innovations because there were no good quantitative endpoints for clinical trials. There was an intensive search going on for markers of that kind, for example biomarkers in the blood, but those markers suffer from huge variability. If you want to reach a clinically relevant conclusion about a particular patient, such variable markers will not do. FRI solves the problem, as we show the individual patient's anatomy as it really is. We have never seen any significant variability unrelated to the disease or the





effect of medication in our studies. So FRI provides stable parameters for clinical trials.'

#### CLINICAL RESEARCH

A recent example of the success of FRI in clinical research is from the Dutch respiratory physician Maarten van den Berge (see the interview with him). Wilfried De Backer: 'The contrast between Van den Berge's study and EUROSCOPE could not be greater. Whereas EUROSCOPE needed three years and 1,200 patients to show a significant difference, Van den Berge achieved that in one month with just 23 patients.' Jan De Backer: 'The study looked at the difference between LABA/LAMA and LABA/LAMA plus inhaled corticosteroids for people with COPD. Thanks to FRI, Dr Van den Berge was able to show convincingly that adding inhaled corticosteroids works significantly better than treating them solely with LABA/LAMA. He also showed where in the lungs the drugs act and what differences there are between patients in which the treatment does and does not work well. Spirometry did not yield any significant results in that study, given the small number of patients involved.'

FRI was behind the development of small-particle inhalers that send the particles deeper into the lungs. Jan De Backer: 'Starting in 2005, we carried out ten to fifteen studies resulting in the approval of drugs using those small particles.' Several completed and current Phase 1-4 clinical trials of drugs for pulmonary disease thus owe their success (or potential future success) to the Fluidda technique.

Researchers are increasingly embracing Functional Respiratory Imaging for clinical trials into new drugs for pulmonary disease. Broncholab is currently being introduced for the routine diagnosis of patients with pulmonary disease in American hospitals, and Europe will probably follow in 2021. As soon as doctors start making widespread use of FRI, the days of non-specific diagnosis using spirometry will be over. FRI is able to map each patient's disease at millimetre-level resolution and monitor the effects of treatment, thus making the prospect of a new scientific and diagnostic gold standard a real possibility.

'It's all coming together now', concludes Jan De Backer. 'In recent years the radiation exposure from CT scans has decreased substantially, treatments have become more and more expensive and the possibilities of data analysis have improved to unprecedented levels. Furthermore, a pandemic is showing the world that we need innovations in pulmonary medicine. The introduction of FRI as a diagnostic technique has come at just the right time.'



Author: Daniel Dresden

# The need to measure

**'My first substantial encounter with quantitative CT imaging has opened my eyes to what can be done', says David Langton, thoracic physician and associate professor at Monash University, Melbourne (Australia), speaking about the need to measure disease activity in patients with diverse airway diseases. 'At the moment, quantitative CT imaging is predominantly used in the research domain, but it is progressively moving to routine clinical practice. Quantitative CT imaging is clearly going to be the future.'**

There is a saying: what gets measured, gets managed. This, of course, assumes management is possible. 'In the past, that measurement didn't make a lot of difference, because the treatments were the same anyway', says David Langton. 'Because of the introduction of new treatments, it in fact is important to differentiate within the spectrum of patients.' With more advanced interventions becoming available, physicians treating respiratory disease have found themselves in need of new, more sensitive forms of measurement.

## SHORTCOMINGS OF FEV1

David Langton first encountered quantitative CT imaging while performing clinical research on asthma patients. 'We were trying to resolve the clinical paradox of why patients felt better after bronchial thermoplasty, which was clearly established in registries and clinical trials, when there didn't seem to be any improvement in FEV1. Either the patients were wrong, and they weren't any better at all, or alternatively the FEV1 was not detecting some other improvement that was happening.'

Although FEV1 is still considered the gold standard for the functional assessment of airway diseases, it does not give an accurate picture of local pathophysiology. 'We had worked out that the FEV1 only tests resistance in the large airways, but doesn't give us information what is happening in the small airways', David Langton added. 'Fittingly, the small airways are often called the silent zone of the lung. We thought that maybe something is happening there that is making the patient feel better, but it is not being detected by the FEV1.' It has long been

## DAVID LANGTON

David Langton studied Medicine at Monash University in Melbourne. After graduation he completed the Royal Australasian College of Physician examinations and specialized in Intensive Care and Respiratory Medicine. He founded the ICU and Respiratory Units at Peninsula Health in Melbourne and later received an Order of Australia Medal for services to the community. In 2016 he completed a Master of Public Health, and more recently a PhD, studying the impact of bronchial thermoplasty in asthma. David Langton has extensive research experience in clinical trials and novel medications, particularly in the field of asthma.



clear that there is an unmet need for additional sensitive outcome parameters.

### FIRST ENCOUNTER WITH QUANTITATIVE CT IMAGING

Functional respiratory imaging (FRI) provides regional information about the lung and allows for the measurement of changes at the level of the lobes and airways. Additionally, it offers the ability to describe how particles move through the airways, including accurate measurements of the regional deposition of inhaled drugs in the lungs.

That is why David Langton and colleagues embraced FRI. 'Using FRI, we were able to measure the volume of the smaller treated airways compared with the untreated airways, before and after bronchial thermoplasty. We were able to clearly show that the volume of the airways increased after the intervention. Now, when I look back, what we learned seemed obvious, which is good, because it makes it right. It wasn't obvious a couple of years ago. In the latest data, we treated the untreated lung and re-imaged again, so we had three time points. We were very happy with the reliability and repeatability of the measurements. For example, we obtained the same results over time in untreated portions of the lung when reimaged.'

### MARRY THE INFORMATION

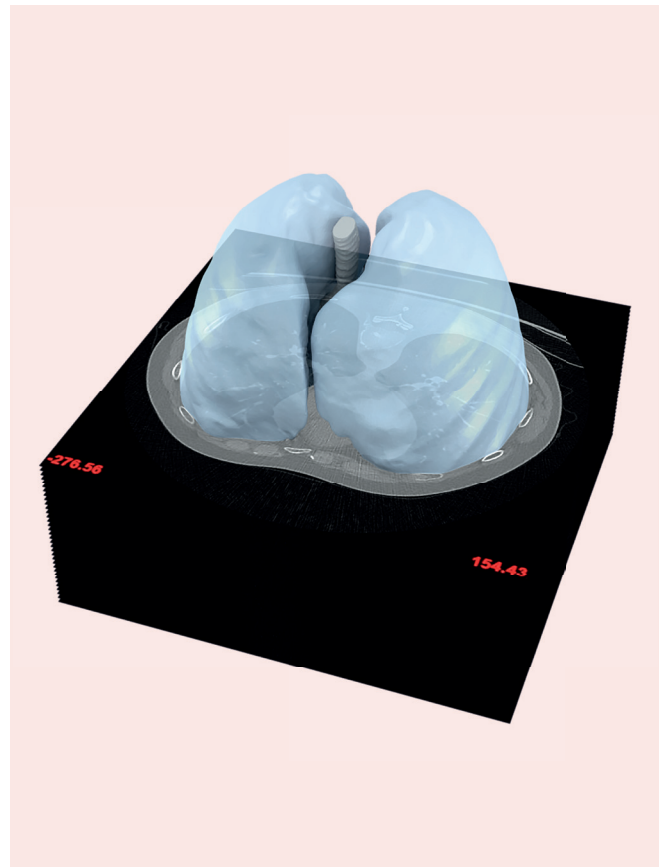
David Langton went on to describe the next step in this development process: 'We were able to marry the information we obtained from the quantitative CT scanning with more complex physiological measurements, to be able to prove that they were showing the same thing. Therefore, we had more than one technique, demonstrating that what we were finding, was correct.'

In performing these studies, David Langton found Fluidda, the company which developed FRI, 'a good company to work with. They were early responsive to our research questions and helping us to answer them. The reporting platform that they use, called broncholab, is very handy, clear, useful, and quickly allows you to compare multiple determinations for the same patient. So, they have got a good platform.'

### APPLICATIONS IN CHRONIC OBSTRUCTIVE AIRWAY DISEASES

Quantitative CT imaging has predominately been used in a clinical research setting. Its use is progressively moving to include routine clinical practice. 'We are now rolling it out into daily clinical practice, for example in bronchial thermoplasty patients', David Langton said. 'This technique is so refined that we can now say: for every patient that we treat, we can determine if he or she has a benefit by comparing the CT scans before and after treatment. So, we have now a reliable tool for routine clinical practice that we can use in every case. At the same time, we are building our case numbers, so that we can learn more and answer other clinical questions in relation to asthma and bronchial thermoplasty.'

David Langton thinks the technique would find application routine clinical practice in other ways as well. 'For example, there is now a whole raft of monoclonal antibodies that we use for the treatment



There is a lot of interest in the world in interstitial lung diseases, like pulmonary fibrosis.

of patients with asthma. It would be very interesting to look at what is happening in the airways before and after treatment. I bet the same thing is happening compared with bronchial thermoplasty.'

#### **FURTHER APPLICATIONS: FIBROSIS AND POST-COVID**

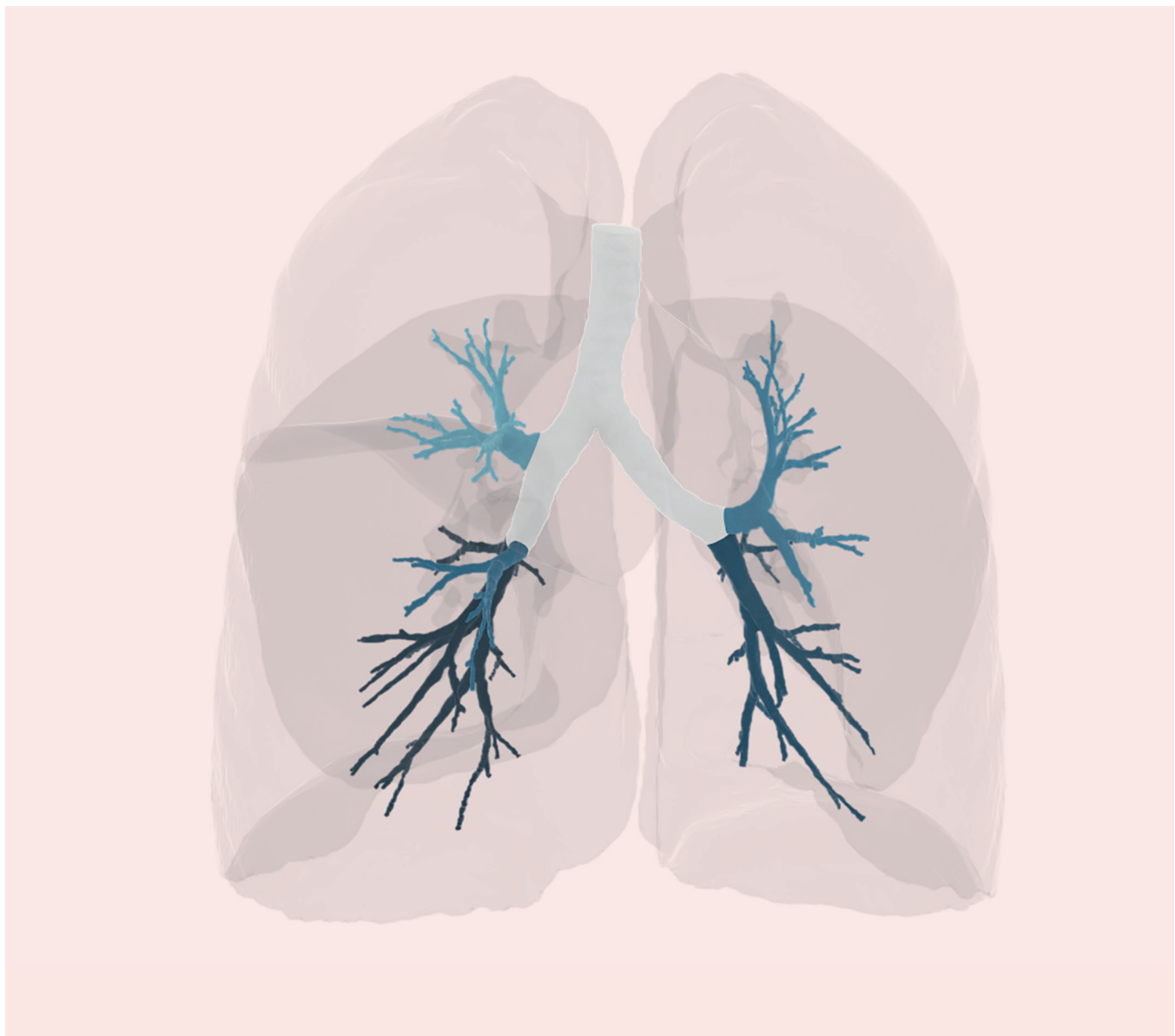It is likely that there will be other applications of this sort of technology as well. 'We have focused on chronic obstructive airway disease, but obviously there is a lot of interest in the world in interstitial lung diseases, like pulmonary fibrosis', David Langton told. 'We know that these patients deteriorate, but the question is how to monitor them. We currently monitor them by asking how they feel and looking at their lung function. We perform serial CT scans, but we just visually decide whether they look the same or a little bit worse. Now, we are clearly possible to quantitative measure that could be used. The same applies for lung transplant patients.'

Another possible application of quantitative imaging, which David


Langton finds interesting, is the potential use in post-COVID patients to monitor fibrosis and other lung lesions. 'We haven't looked at it, I do not think that anybody will have looked at it. It could be very interesting.'

#### **LIVE HAPPIER AND HOPEFULLY LONGER**

For personalized treatment, there is a need for improved understanding of disease pathophysiology and recognition of disease heterogeneity and complexity. According to David Langton, FRI is very useful in meeting this challenge. The ultimate goal is that with the guidance of quantitative imaging treatments can become more individualized, so that patients will live happier and hopefully longer. David Langton thinks that quantitative imaging has the potential to accomplish this goal.







Author: Michiel Tent

# FRI adds an important dimension to conventional imaging techniques

## MUHUNTHAN THILLAI

Muhunthan Thillai (BA PhD MBBS MRCP) graduated from St Mary's Medical School in 2002. He began his training as a junior doctor in London and Oxford, where he gained membership of the Royal College of Physicians. He was then appointed as the Infectious Diseases Fellow on the Map of Medicine project at NHS Connecting for Health. Three years of research into sarcoidosis culminated in a PhD in Immunology and Proteomics from Imperial College London in 2012.

Dr. Thillai continued his medical training at Papworth and Addenbrooke's Hospital. He subsequently completed an observership in sarcoidosis at the Cleveland Center (USA), before being appointed as a Consultant within the Papworth Interstitial Lung Diseases Unit with a specific interest in sarcoidosis in 2015. He continues to attend a regular outpatient clinic at Addenbrooke's Hospital and maintains ongoing research links with Imperial College London.

Dr. Thillai is the co-founder and CEO of Qur8 ([www.qureight.com](http://www.qureight.com)), an imaging platform for analyzing large clinical data sets using FRI, among other techniques. Qur8's main focus is on respiratory medicine; its primary goal is to analyze clinical trial data in innovative ways.

**There are two reasons why Dr. Muhunthan Thillai is highly interested in functional respiratory imaging (FRI) and uses it in his research. First, because he is a pulmonologist specializing in pulmonary fibrosis; and secondly, because he is the co-founder and CEO of Qur8, an imaging platform where FRI is a helpful tool for analyzing large clinical sets of data. He details two very recent studies – of fibrosis and of COVID-19 patients – in which FRI has played a pivotal role.**

Dr. Thillai emphasizes the added value of FRI compared with more conventional techniques measuring lung function and volume. 'FRI can by no means replace those techniques; what it does is add an important dimension. FRI allows you to quantify disease level over a period of time to demonstrate whether the disease is improving, stabilizing or deteriorating. As FRI is based on an image at a set point in time, there is less variability than with conventional measures. In addition, FRI can quantify large amounts of volume data that lung function testing cannot.' FRI offers improved visualization of airways, blood vessels and other anatomical structures. It provides detailed information not only about lung and lobar volume, but also on airway resistance, internal airflow distribution, aerosol deposition, nodule volume, and many other variables.

## FRI was found to be a safe, robust mechanism for assessing airway volume.

### FRI IDENTIFIES IPF PROGRESSION

One of the fields of research where Dr. Thillai uses FRI is idiopathic pulmonary fibrosis (IPF). Options for determining the disease course in patients with IPF are limited. A recent study Dr. Thillai was involved in hypothesized that FRI could identify patients with more progressive IPF between two CT time points.[1] Two separate cohorts of IPF patients were identified: 12 patients with stable IPF and 12 patients with progressive disease. FRI was found to be a safe, robust mechanism for assessing airway volume. Thillai explains: 'It was shown for the very first time that specific airway volume ( $siV_{aw}$ ) can be used to help identify IPF patients with progressive disease. Obviously, we need to do a lot more research, but we have shown that airway volumes increase in progressing patients, whereas they do not change in stable patients. This seems to be a useful additional piece of information; measuring  $siV_{aw}$  is by no means meant to replace existing assessment tools.' Dr. Thillai explains that this information can be used to monitor disease course; to help determine which patients are progressing and may therefore be candidates for certain treatments; and to help evaluate the effectiveness of any of these therapies. 'As some of the available drugs are very expensive, they are reserved for patients who get worse. However, when patients are relatively well, it may be difficult to establish whether they are deteriorating. Serial FRI measurements could be sufficiently sensitive to show that patients are progressing microscopically.'

### HYPOXEMIA IN COVID-19 PATIENTS

In 2020, Dr. Thillai has also been involved in COVID-19-related studies. One of these studies, he explains, originated from the observation that some patients with COVID-19 have relatively normal lung capacity and lung function, but they still have significant hypoxemia different from typical acute respiratory distress syndrome (ARDS). 'We hypothesized that insufficient blood supply was contributing to the low levels of oxygen in these patients.[2] We used FRI to calculate pulmonary blood volume.' FRI was performed on CT scans from intubated patients with COVID-19 ( $n = 10$ ) and compared with data from matched intubated ARDS patients ( $n = 7$ ) and a retrospective group of healthy controls ( $n = 107$ ). Volumes of blood were computed from the cross-sectional area of each vessel:  $<5 \text{ mm}^2$  was defined as small. Dr. Thillai

notes: 'FRI allowed us to observe differences in blood volume distribution between the three groups. The small blood vessels in the lungs were highly constricted in COVID-19 patients, but not in the other two groups. That may explain the hypoxemia in these patients.'

Dr. Thillai and his group gathered additional lung CT scans that allow for longitudinal analysis of the lung blood vessels, which they are now performing. 'We want to know if changes in the lung vessels correlate with the clinical condition of patients over time: if they recover, do the blood vessels in the lungs also return to normal?' Thillai speculates that the increased vascular resistance observed may be caused either by vasoconstriction of distal pulmonary arteries or by the presence of numerous microthrombi.

Apart from helping to gain insight into the mechanisms of COVID-19, the results of this study may have various clinical implications. They confirm that high positive end-expiratory pressure (PEEP) alone is not enough to oxygenate these patients. 'If microthrombi play a causative role, perhaps stronger anticoagulation should be given; if vasoconstriction is the main cause, the use of pulmonary vasodilators should perhaps be considered. These issues should be addressed in future research.'

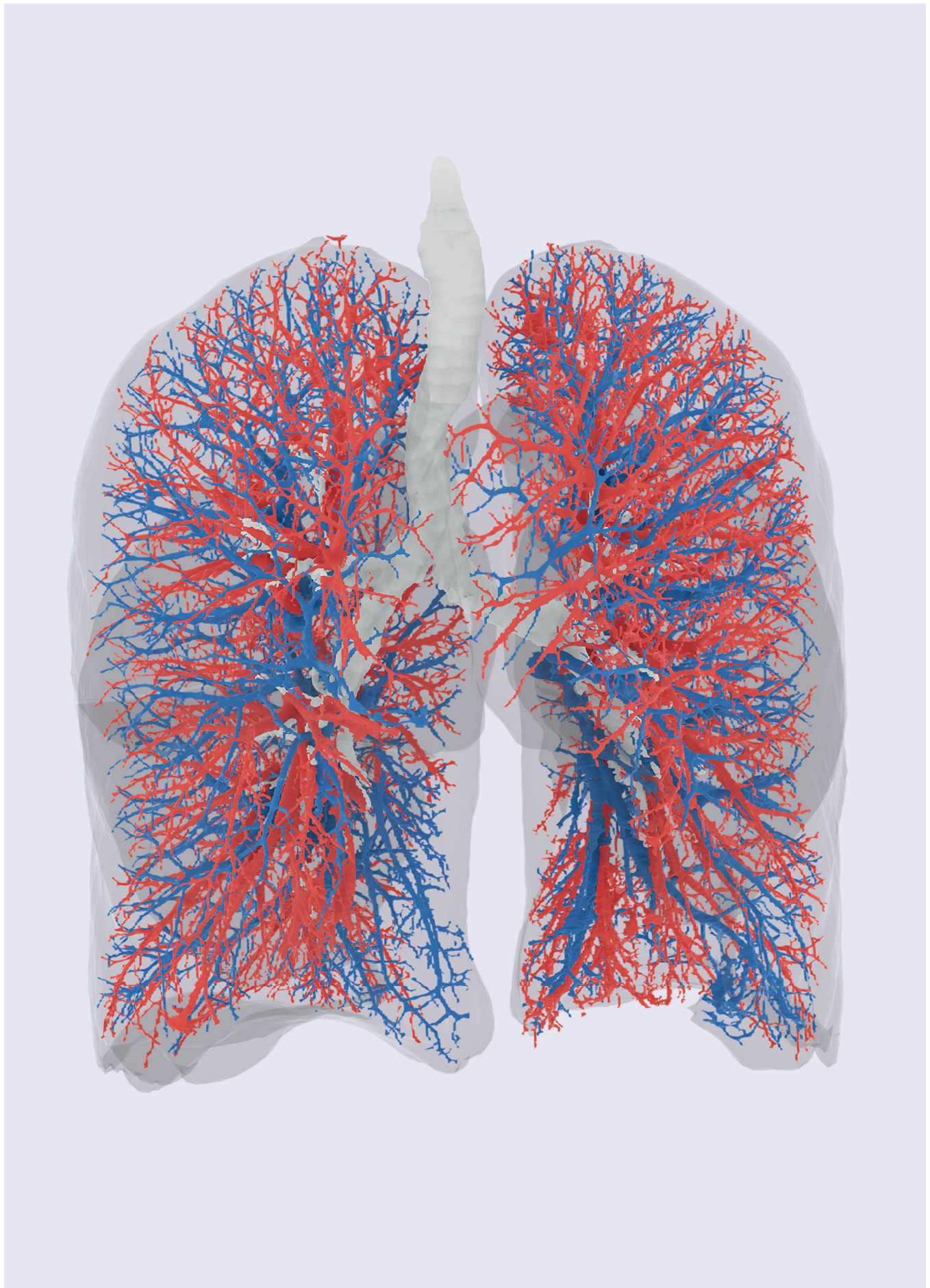
### NUMEROUS APPLICATIONS

Imaging techniques will gain in importance in lung diseases, Dr. Thillai expects. 'Since both the radiation dose and the cost have come down, CT scans will play an even bigger role in lung imaging. FRI provides valuable additional information to assist the radiologist, the pathologist, the pulmonologist. The applications are manifold: diagnostics, clinical trials, personalized medicine, et cetera. With personalized medicine on the rise, FRI data can help physicians determine if a treatment is effective in trials and continues to be so afterwards. Everybody gains: patients, physicians and society at large, because expensive drugs can be confined to those patients in which they really work.'

### REFERENCES

1. McLellan T, George PM, Ford P, et al. Idiopathic pulmonary fibrosis: airway volume measurement identifies progressive disease on computed tomography scans. *ERJ Open Res.* 2020; 6(1):00290-2019.
2. Thillai M, Patvardhan C, Swietlik EM, et al. Functional respiratory imaging identifies redistribution of pulmonary blood flow in patients with COVID-19. *Thorax.* 2020 Aug 28;thoraxjnl-2020-215395. DOI: 10.1136/thoraxjnl-2020-215395.









Author: Daniel Dresden

# The advent, value and place of quantitative imaging

**Quantitative imaging is the future: that is the expectation of Dr. Firdaus Mohamed Hoesein, chest radiologist at UMC Utrecht, who explains why: 'It is difficult for radiologists to assess the percentage of affected lung precisely on a pulmonary scan. There is a clear need to ascertain precisely how much lung tissue is affected and be able to express it as a number. This way we can also measure and monitor disease progression and treatment outcomes over time.'**

Quantitative imaging uses a computer algorithm to indicate numerically how much disease activity there is. 'That is a major gain compared to the way we radiologists currently operate', thinks Mohamed Hoesein.

## QUALITATIVE VERSUS QUANTITATIVE

At present, scans are assessed visually, i.e. qualitatively, which makes it difficult to determine the quantity, i.e. the extent of the disease. 'We look at a scan and say, for example, there is a little bit of emphysema', as the Utrecht radiologist describes the current approach. 'Also, radiologists are unable to detect some subtle abnormalities that a computer can detect. And how those abnormalities are classified can differ from one radiologist to another. One problem is that, when a fellow radiologist looks at the same scan, it is difficult to compare the results if we only consider qualitative measures, and that is true of follow-ups too. It is difficult for a human to detect a minor increase in emphysema, there is no yardstick for that.' There is therefore a need for measurement, in addition to the work of the radiologist.

## FIRDAUS MOHAMED HOESEIN

Firdaus Mohamed Hoesein studied medicine at Utrecht University the Netherlands. After obtaining his medical degree he performed research at the Department of Respiratory Medicine at the University Medical Center Utrecht (UMCU) in the Netherlands focussing on the role of quantitative CT imaging of the lungs. This resulted in a PhD in Respiratory Medicine in 2012. Dr. Mohamed Hoesein did a Radiology residency at the Department of Radiology of the UMCU and is a board-certified radiologist since 2017. He did a 1-year fellow-ship in thoracic imaging and has been working as a consultant thoracic radiologist at the UMCU since 2018. Dr. Mohamed Hoesein received several awards for his research on quantitative imaging in lung disease.

Quantitative imaging, e.g. Functional Respiratory Imaging (FRI, see [www.fluidda.com](http://www.fluidda.com)) is able to show various aspects of airway problems, such as airway resistance, air trapping and ventilation mapping.

### COMPREHENSIVE MEASUREMENT VERSUS LOCAL DISEASE ACTIVITY

A limitation of the lung function test is that it gives a value for the lung as a whole. The first limitation of spirometry that Mohamed Hoesein points out is that 'it is not clear where the problem lies, in the left or right lung, the upper or lower lobe'. 'On the CT scan you can see where the problem lies, for example in the left lower lobe, or conversely spread equally over the lobes. Another problem with the lung function test is that the results depend on whether patients do their best.'

If only a small proportion of the lungs is affected and the other parts are still functioning normally, a lung function test will often not detect the disease activity, as the lung function is still normal on average. 'In cases of COPD, for instance, we know that patients can have air trapping, emphysema and airway wall disease while their FEV1 is still normal. We can see those abnormalities on a CT scan. Quantitative imaging is definitely useful if the abnormality is not clear visually and the lung function is still normal.' Mohamed Hoesein consequently expects that quantitative imaging will be able to play a role especially during early disease stages and in prognosis.

### MOHAMED HOESEIN'S RESEARCH INTO COPD AND COVID-19

Clinical drug trials often look at the effects on lung function, but if that improves only slightly, it is difficult to show major differences. The abnormalities will differ significantly on the scan, however, says Mohamed Hoesein. 'If we can measure that, it will benefit drug research.'

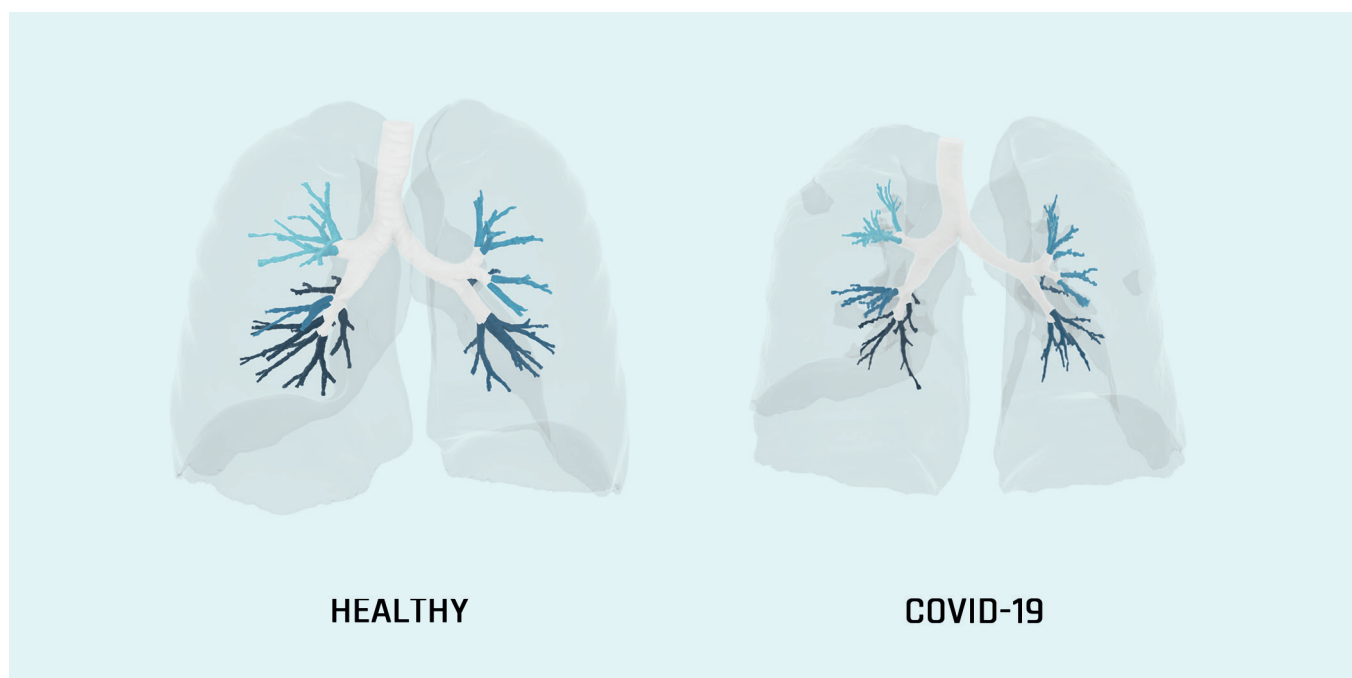
In their own research into quantitative imaging, Mohamed Hoesein and his colleagues found that some people with normal lung function already had emphysema. Lung function deteriorated more rapidly in patients already showing emphysema than in those with no emphysema and the same lung function. Over a longer follow-up period the dimensions on the CT scan have been found to be predictive.

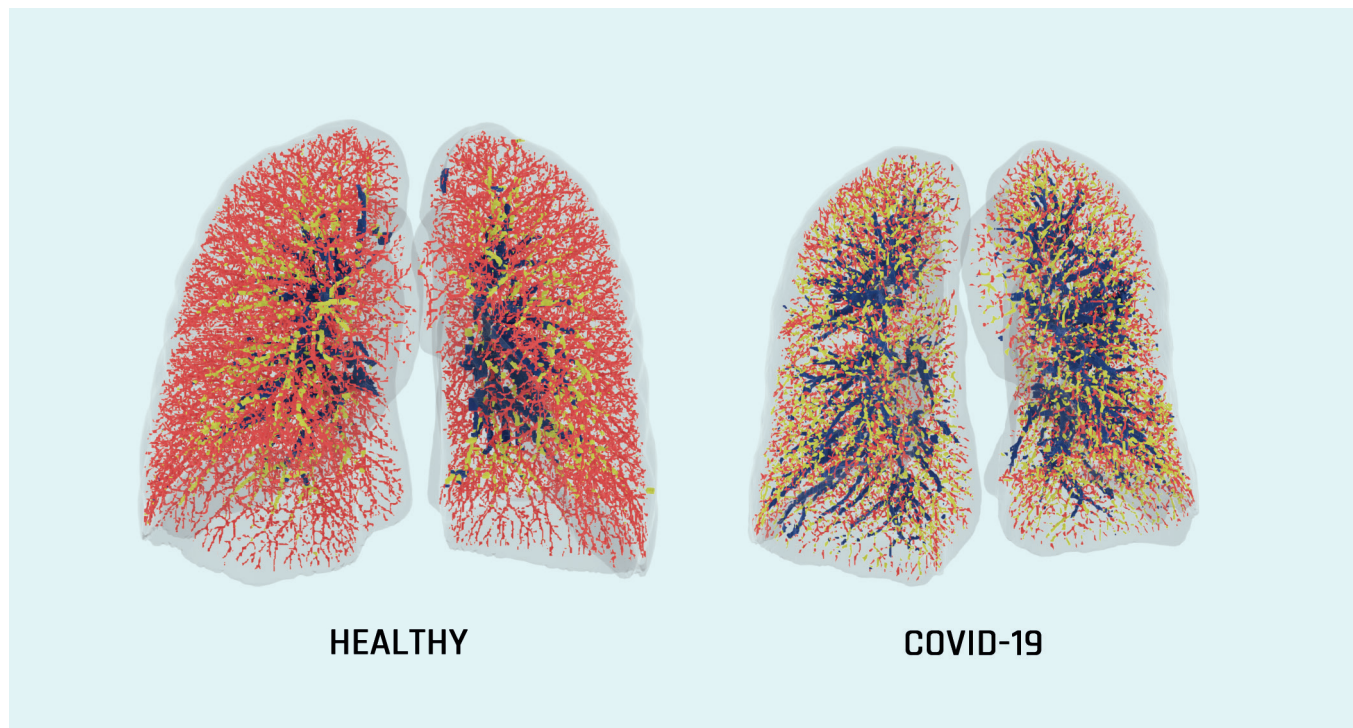
There is a good deal of interest currently in the radiological abnormalities found in COVID-19 patients. The long-term effects of COVID-19 in patients who have been admitted to hospital with that infection are being surveyed in a nationwide research program, known as Precision Medicine for more Oxygen (P4O2).[1] Mohamed Hoesein is the program's Principal Investigator responsible for the Imaging part of the program. 'We are using FRI to predict at an early stage which patients will deteriorate rapidly and who will have residual damage.'

The researchers are looking at the role played by the pulmonary blood vessels in COVID-19 patients, for instance. 'It would be interesting to find out whether the lung vasculature is different in patients with residual damage', notes Mohamed Hoesein. 'The blood vessel volume can be ascertained using FRI. The idea is that the blood vessel volume will be different in patients with severe COVID-19.[2]

### CHRONIC ILLNESSES IN PARTICULAR

In Mohamed Hoesein's opinion, quantitative imaging is useful in all lung diseases, but it could play a major role particularly in the long-term follow-up of patients with a chronic illness such as COPD, bronchiolitis obliterans, cystic fibrosis (CF), chronic respiratory tract infections or patients who have previously had a lung transplant. 'It is important to identify the long-term effects. Quantitative imaging could also play a role in patients who cannot do a lung function test, for instance because of COVID-19, as the





“ **A limitation of the lung function test is that it gives a value for the lung as a whole.** ”

test entails an increased risk of transmitting SARS-CoV-2. In those cases we can do a CT scan.’

Quantitative imaging has added value in patients with CF, as their lung function has already deteriorated a priori. An improvement of only a few percent in a patient with poor lung function is difficult to measure using a normal CT scan. ‘Those patients may be recovering well clinically, despite having substantial abnormalities on the scan’, says the Utrecht radiologist. ‘If we can identify those abnormalities on the scan, we can measure the disease activity better than with a lung function test.’

#### TRULY PERSONALIZED MEDICINE

We are living in a period of personalized health care technology, such as smart watches that can analyze heart rhythms in real time. In the future, Mohamed Hoesein expects that patients will want to receive the data from their CT scans. ‘They will then have a value that tells them what their lungs are like, in other words what proportion of the lungs is functioning properly and what proportion is affected. The CT scan provides a snapshot of the

lungs at that time, in other words truly personalized medicine. We will want to have it quantified, although that will take a while yet.’ Currently, respiratory physicians check lung function every six months, for example, and plot any decrease or increase on a graph. The time will come when we can do that with these CT values, with patients being monitored over time. ‘We can act quickly if there is any acute deterioration.’

#### EXPECTED PLACE

In the short term, Mohamed Hoesein expects that quantitative imaging will have a place mainly in clinical research, but in the long term, it may also have a place in the daily practice. ‘It will be comparable to lab results. In future, we shall have various values from the CT scan, such as the degree of emphysema and the airway wall thickness. It may also be possible to measure the cardiac calcium score. Body composition, for example the amount of fat and muscle mass, may also be able to be determined from the CT scan. In future, respiratory physicians may be able to use that to decide whether or not to initiate and continue a treatment.’

#### REFERENCES

1. COVID extension of P402 <https://p4o2.org/work-packages/covid-extension-of-p4o2>.
2. Thillai M, Patvardhan C, Swietlik EM, et al. Functional respiratory imaging identifies redistribution of pulmonary blood flow in patients with COVID-19. *Thorax*. 2020;thoraxjnl-2020-215395.



# FRI

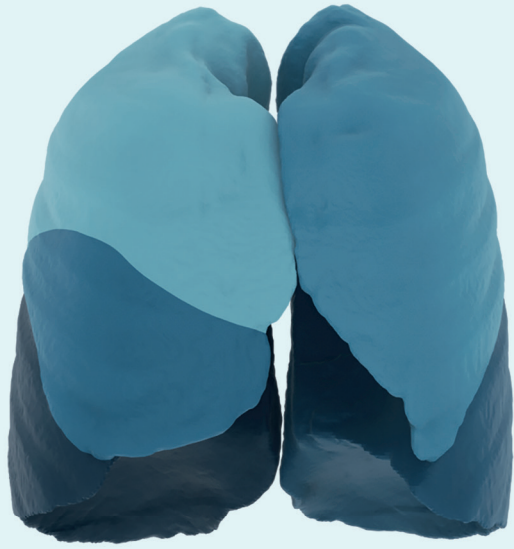

# Publications

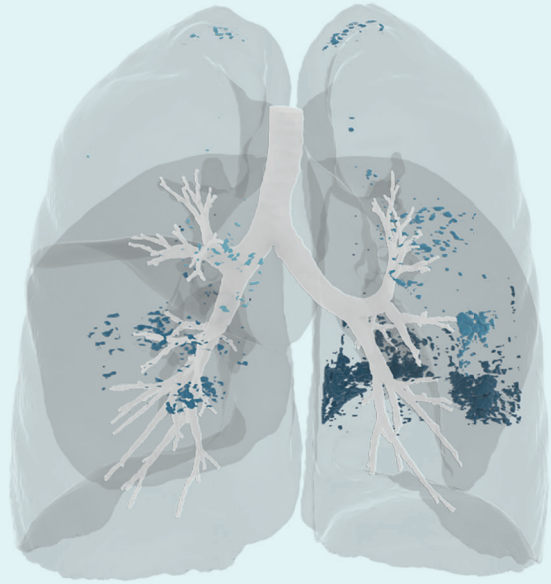# Papers

- Barbosa, E. J. M. Jr, Lanclus, M., Vos, W., Van Holsbeke, C., De Backer, W., De Backer, J. & Lee, J. (2018) Machine learning algorithms utilizing quantitative CT features may predict eventual onset of bronchiolitis obliterans syndrome after lung transplantation. *Academic Radiology* 25(9), 1201-1212.
- Bos, A. C., van Holsbeke, C., De Backer, J. W., van Westreenen, M., Janssens, H. M., Vos, W. G. & Tiddens, H. A. W. M. (2015) Patient-specific modeling of regional antibiotic concentration levels in airways of patients with cystic fibrosis: are we dosing high enough? *PLoS ONE* 10(3), e0118454.
- Burrows, K. S., De Backer, J., Smallwood, R., Sterk, P. J., Gut, I., Wirix-Speetjens, R., Siddiqui, S., Owers-Bradley, J., Wild, J., Maier, D. & Brightling C. (2013) Multi-scale computational models of the airways to unravel the pathophysiological mechanisms in asthma and chronic obstructive pulmonary disease (AirPROM). *Interface Focus* 3, 20120057.
- Burrows, K. S., De Backer, J. & Kumar, H. (2017) Image-based computational fluid dynamics in the lung: Virtual reality or new clinical practice. *WIREs Systems Biology and Medicine* e1392.
- Clukers, J., Lanclus, M., Mignot, B., Van Holsbeke, C., Roseman, J., Porter, S., Gorina, E., Kouchakji, E., Lipson, K. E., De Backer, W. & De Backer, J. (2018) Quantitative CT analysis using functional imaging is superior in describing disease progression in idiopathic pulmonary fibrosis compared to forced vital capacity. *Respiratory Research* 19, 213.
- De Backer, J. W., Vanderveken, O. M., Vos, W. G., Devolder, A., Verhulst, S. L., Verbraecken, J. A., Parizel, P. M., Braem, M. J., Van de Heyning, P. H. & De Backer W. A. (2007) Functional imaging using computational fluid dynamics to predict treatment success of mandibular advancement devices in sleep-disordered breathing. *Journal of Biomechanics* 40, 3708-3714.
- De Backer, J. W., Vos, W. G., Devolder, A., Verhulst, S. L., Germonpré, P., Wuyts, F. L., Parizel, P. M. & De Backer, W. (2008) Computational fluid dynamics can detect changes in airway resistance in asthmatics after acute bronchodilation. *Journal of Biomechanics* 41, 106-113.
- De Backer, J. W., Vos, W. G., Gortlé, C. D., Germonpré, P., Partoens, B., Wuyts, F. L., Parizel, P. M. & De Backer, W. (2008) Flow analyses in the lower airways: Patient-specific model and boundary conditions. *Medical Engineering & Physics* 30, 872-879.
- De Backer, J. W., Vos, W. G., Verhulst, S. L., De Backer, W. (2008) Novel imaging techniques using computer methods for the evaluation of the upper airway in patients with sleep-disordered breathing: A comprehensive review. *Sleep Medicine Reviews* 12, 437e447.
- De Backer, J. W., Vos, W. G., Burnell, P., Verhulst, S. L., Salmon, P., De Clerck, N. & De Backer, W. (2009) Study of the variability in upper and lower airway morphology in Sprague-Dawley rats using modern micro-CT scan-based segmentation techniques. *The Anatomical Record* 292, 720-727.
- De Backer, J. W., Vos, W. G., Vinchurkar, S.C., Claes, R., Drollmann, A., Wulfrank, D., Parizel, P. M., Germonpré, P. & De Backer, W. (2010) Validation of computational fluid dynamics in CT-based airway models with SPECT/CT. *Radiology* 257(3), 854-862.
- De Backer, L. A., Vos, W. G., Salgado, R., De Backer, J. W., Devolder, A., Verhulst, S. L., Claes, R., Germonpré, P. R. & De Backer, W. A. (2011) Functional imaging using computer methods to compare the effect of salbutamol and ipratropium bromide in patient-specific airway models of COPD. *International Journal of COPD* 6, 637-646.
- De Backer, L., Vos, W., Dieriks, B., Daems, D., Verhulst, S., Vinchurkar, S., Ides, K., De Backer, J., Germonpré, P. & De Backer, W. (2011) The effects of long-term noninvasive ventilation in hypercapnic COPD patients: a randomized controlled pilot study. *International Journal of COPD* 6, 615-624.
- De Backer, L. A., Vos, W., De Backer, J., van Holsbeke, C., Vinchurkar, S. & De Backer, W. (2012) The acute effect of budesonide/formoterol in COPD: a multi-slice computed tomography and lung function study. *European Respiratory Journal* 40, 298-305.
- De Backer, J., Vos, W., van Holsbeke, C., Vinchurkar, S., Claes, R., Parizel, P. M. & De Backer, W. (2013) Effect of high-dose N-acetylcysteine on airway geometry, inflammation, and oxidative stress in COPD patients. *International Journal of COPD* 8, 569-579.
- De Backer, W., Vos, W., van Holsbeke, C., Vinchurkar, S., Claes, R., Hufkens, A., Parizel, P. M., Bedert, L. & De Backer, J. (2014) The effect of roflumilast in addition to LABA/LAMA/ICS treatment in COPD patients. *European Respiratory Journal* 44(2), 527-529.
- De Backer, J., Vos, W., Vinchurkar, S., van Holsbeke, C., Poli, G., Claes, R., Salgado, R. & De Backer, W. (2015) The effects of extrafine beclometasone/formoterol (BDP/F) on lung function, dyspnea, hyperinflation, and airway geometry in COPD patients: Novel insight using functional respiratory imaging. *Journal of Aerosol Medicine and Pulmonary Drug Delivery* 28(2), 88-99.
- De Backer, J., van Holsbeke, C., Vos, W., Vinchurkar, S., Dorinsky, P., Rebello, J., Mangale, M., Hajian, B. & De Backer, W. (2016) Assessment of lung deposition and analysis of the effect of fluticasone/salmeterol hydrofluoroalkane (HFA) pressurized metered dose inhaler (pMDI) instable persistent asthma patients using functional respiratory imaging. *Expert Review of Respiratory Medicine* 10(8), 927-933.
- De Backer, W., De Backer, J., Vos, W., Verlinden, I., van Holsbeke, C., Clukers, J., Hajian, B., Siddiqui, S., Jenkins, M., Reisman, C. & Martin U. J. (2018) a randomized study using functional respiratory imaging to characterize bronchodilator effects of glycopyrrolate/formoterol fumarate delivered by a metered dose inhaler using co-suspension delivery technology in patients with COPD. *International Journal of COPD* 13, 2673-2684.
- De Backer et al. Functional respiratory imaging assessment of glycopyrrolate and formoterol fumarate metered dose inhalers formulated using co-suspension delivery technology in patients with COPD. *Ther Adv Respir Dis.* 2020, Vol. 14: 1-13
- Hajian, B., De Backer, J., Vos, W., van Holsbeke, C., Clukers, J. & De Backer, W. (2016) Functional respiratory imaging (FRI) for optimizing therapy development and patient care. *Expert Opinion on Drug Delivery* 10(2), 193-206.
- Hajian, B., De Backer, J., Vos, W., Aerts, J., Clukers, J. & De Backer, W. (2016) Efficacy of inhaled medications in asthma and COPD related to disease severity. *Expert Opinion on Drug Delivery* 13(12), 1719-1727.
- Hajian, B., De Backer, J., Vos, W., van Holsbeke, C., Ferreira, F., Quinn, D. A., Hufkens, A., Claes, R. & De Backer, W. (2016) Pulmonary vascular effects of pulsed inhaled nitric oxide in COPD patients with pulmonary hypertension. *International Journal of COPD* 11, 1533-1541.
- Hajian, B., De Backer, J., Sneyers, C., Ferreira, F., Barboza, K. C., Leemans, G., Vos, W. & De Backer, W. (2017) Pathophysiological mechanism of long-term noninvasive ventilation in stable hypercapnic patients with COPD using functional respiratory imaging. *International Journal of COPD* 12, 2197-2205.
- Hajian, B., De Backer, J., Vos, W., van Geffen, W. H., De Winter, P., Usmani, O., Cahn, T., Kerstjens, H. A. M., Pistolesi, M. & De Backer, W. (2018) Changes in ventilation-perfusion during and after an COPD exacerbation: an assessment using fluid dynamic modeling. *International Journal of COPD* 13, 833-842.
- Hendeles, L., Daley-Yates, P. T., Hermann, R., De Backer, J., Dissanayake, S. & Horhota, S. T. (2015) Pharmacodynamic studies to demonstrate bioequivalence of oral inhalation products. *The AAPS Journal* 17(3), 758-768.
- Henderson, W. R., Molget-Seon, Y., Vos, W., Lipson, R., Ferreira, F., Kirby, M., van Holsbeke, C., Dominelli, P. B., Griesdale, D. E. G., Sekhon, M., Coxson, H. O., Mayo, J. & Sheel A. W. (2016) Functional respiratory imaging, regional strain, and expiratory time constants at three levels of positive end expiratory pressure in an ex vivo pig model. *Physiological Reports* 4(23), e13059.
- Horemans, B., van Holsbeke, C., Vos, W., Darchuk, L., Novakovic, V., Fontan, A. C., De Backer, J., Van Grieken, R., De Backer, W. & De Wael, K. (2012) Particle deposition in airways of chronic respiratory patients exposed to an urban aerosol. *Environmental Science & Technology* 46(21), 12162-12169.
- Ides, K., Vos, W., De Backer, L. A., Visser, D., Claes, R., Leemans, G., Ongena, K., Peters, O. & De Backer, W. (2012) Acute effects of intrapulmonary percussive ventilation in COPD patients assessed by using conventional outcome parameters and a novel computational fluid dynamics technique. *International Journal of COPD* 7, 667-671.
- Iwanaga, T., Kozuka, T., Nakanishi, J., Yamada, K., Nishiyama, O., Sano, H., Murakami, T. & Tohda, Y. (2017) Aerosol deposition of inhaled corticosteroids/long-acting B2-agonists in the peripheral airways of patients with asthma using functional respiratory imaging, a novel imaging technology. *Pulmonary Therapy* 3, 219-231.

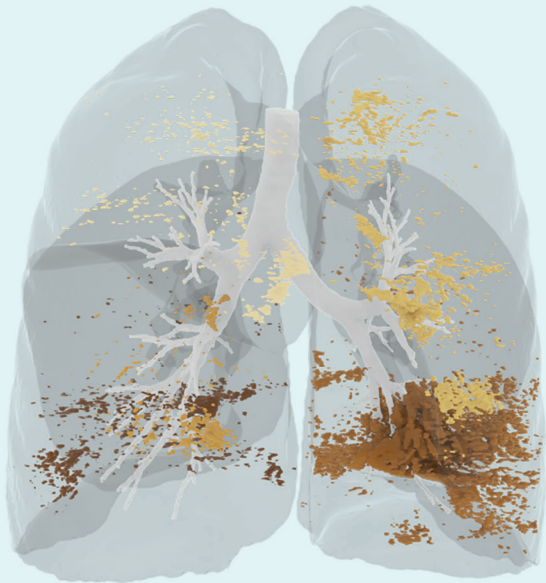
31. Janssens, A., Vos, W., van Holsbeke, C., Van Schil, P., Oostveen, E., De Backer, J., Carp, L., Snoeckx, A., De Backer, W. & van Meerbeeck, J. P. (2015) Estimation of post-operative forced expiratory volume by functional respiratory imaging. *European Respiratory Journal* 45, 544-546.
32. Kim, M., Bordas, R., Vos, W., Hartley, R. A., Brightling, C. E., Kay, D., Grau, V. & Burrowes, K. S. (2015) Dynamic flow characteristics in normal and asthmatic lungs. *International Journal for Numerical Methods in Biomedical Engineering* 31(12), e02730.
33. Lanclus, M., Clukers, J., van Holsbeke, C., Vos, W., Leemans, G., Holbrechts, B., Barboza, K., De Backer, W. & De Backer, J. (2019) Machine learning algorithms utilizing functional respiratory imaging may predict COPD exacerbations. *Academic Radiology* 26(9), 1191-1199.
34. Langton, D., Sloan, G., Banks, C., Bennetts, K., Plummer, V. & Thien, F. (2019) Bronchial thermoplasty increases airway volume measured by functional respiratory imaging. *Respiratory Research* 20, 157.
35. Langton et al. Bronchial thermoplasty reduces airway resistance. *Respiratory Research* (2020) 21:76
36. Leemans et al. A Functional Respiratory Imaging Approach to the Effect of an Oscillating Positive Expiratory Pressure Device in Chronic Obstructive Pulmonary Disease. *International Journal of Chronic Obstructive Pulmonary Disease* 2020:15 1261-1268
37. Leemans et al. The effectiveness of a mobile high-frequency chest wall oscillation (HFCWO) device for airway clearance.
38. Lins et al. Assessment of small pulmonary blood vessels in Covid-19 patients using HRCT. *Academic Radiology*, Vol 27, No 10, October 2020
39. Maher, T. M., van der Aar, E. M., Van de Steen, O., Allamassey, L., Desrivot, J., Dupont, S., Fagard, L., Ford, P., Fieuw, A. & Wyuts, W. (2018) Safety, tolerability, pharmacokinetics, and pharmacodynamics of GLPG1690, a novel autotaxin inhibitor, to treat idiopathic pulmonary fibrosis (FLORA): a phase 2a randomised placebo-controlled trial. *Lancet Respiratory Medicine* 6(8), 627-635.
40. Marchandise, E., Carton de Wiart, C., Vos, W. G., Geuzaine, C. & Remacle J. -F. (2011) High-quality surface remeshing using harmonic maps—Part II: Surfaces with high genus and of large aspect ratio. *International Journal for Numerical Methods in Engineering* 86, 1303-1321.
41. McLellan, T., George, P. M., Ford, P., De Backer, J., van Holsbeke, C., Mignot, B., Screaton, N. J., Ruggiero, A. & Thillai, M. (2020) Idiopathic pulmonary fibrosis: airway volume measurement identifies progressive disease on computed tomography scans. *ERJ Open Research* 6(1), 00290-2019.
42. McLellan T, George PM, Ford P, et al. Idiopathic pulmonary fibrosis: airway volume measurement identifies progressive disease on computed tomography scans. *ERJ Open Res* 2020; 6: 00290-2019
43. Ruscitti, F., Ravanetti, F., Essers, J., Ridwan, Y., Belenkov, S., Vos, W., Ferreira, F., KleinJan, A., van Heijningen, P., van Holsbeke, C., Cacchioli, A., Villetti, G. & Stellari, F. F. (2017) Longitudinal assessment of bleomycin-induced lung fibrosis by Micro-CT correlates with histological evaluation in mice. *Multidisciplinary Respiratory Medicine* 12, 8.
44. Schepens, T., Cammu, G., Maes, S., Desmedt, B., Vos, W., & Deseure, K. (2016) Functional respiratory imaging after neostigmine- or sugammadex-enhanced recovery from neuromuscular blockade in the anaesthetised rat: a randomized controlled pilot study. *Revista Brasileira De Anestesiologia* 67(5), 443-449.
45. Schepens et al. Functional respiratory imaging of the airways in the acute respiratory distress syndrome. *Anaesthesia Critical Care & Pain Medicine*, Volume 39, Issue 2, April 2020, Pages 207-213.
46. Slaats, M. A., Van Hoorenbeek, K., Van Eyck, A., Vos, W. G., De Backer, J. W., Boudewyns, A., De Backer, W. & Verhulst, S. L. (2015) Upper airway imaging in pediatric obstructive sleep apnea syndrome. *Sleep Medicine Reviews* 21, 59-71.
47. Slaats, M. A., Vos, W., van Holsbeke, C., De Backer, J., Loterman, D., De Backer, W., Boudewyns, A. & Verhulst, S. (2017) Predicting the effect of treatment in paediatric OSA by clinical examination and functional respiratory imaging. *Pediatric Pulmonology* 52(6), 799-805.
48. Tahir, B. A., Swift, A. J., Marshall, H., Parra-Robles, J., Hatton, M. Q., Hartley, R., Kay, R., Brightling, C. E., Vos, W., Wild, J. M. & Ireland, R. H. (2014) A method for quantitative analysis of regional lung ventilation using deformable image registration of CT and hybrid hyperpolarized gas/<sup>1</sup>H MRI. *Physics in Medicine & Biology* 59, 7267-7277.
49. Tahir, B. A., Van Holsbeke, C., Ireland, R. H., Swift, A. J., Horn, F. C., Marshall, H., Kenworthy, J. C., Parra-Robles, J., Hartley, R., Kay, R., Brightling, C. E., De Backer, J., Vos, W. & Wild, J. M. (2016) Comparison of CT-based lobar ventilation with <sup>3</sup>He MR imaging ventilation measurements. *Radiology* 278(2), 585-592.
50. Thillai M, et al. Functional respiratory imaging identifies redistribution of pulmonary blood flow in patients with COVID-19. *Thorax* 2020; 0:1-3. doi:10.1136
51. Van Geffen, W. H., Hajian, B., Vos, W., De Backer, J., Cahn, A., Usmani, O. S., Van Holsbeke, C., Pistolesi, M., Kerstjens, H. A. M. & De Backer, W. (2018) Functional respiratory imaging: heterogeneity of acute exacerbations of COPD. *International Journal of COPD* 13, 1783-1792.
52. Vanhaverbeke K, Slaats M, Al-Nejar M, et al. Functional respiratory imaging provides novel insights into the long-term respiratory sequelae of bronchopulmonary dysplasia. *Eur Respir J* 2020.
53. Van Holsbeke, C., De Backer, J., Vos, W., Verdonck, P., Van Ransbeeck, P., Claessens, T., Braem, M., Vanderveken, O. & De Backer, W. (2011) Anatomical and functional changes in the upper airways of sleep apnea patients due to mandibular repositioning: A large scale study. *Journal of Biomechanics* 44, 442-449.
54. Van Holsbeke, C., Vos, W., Van Hoorenbeek, K. V., Boudewyns, A., Salgado, R., Verdonck, P. R., Ramet, J., De Backer, J., De Backer, W. & Verhulst, S. L. (2013) Functional respiratory imaging as a tool to assess upper airway patency in children with obstructive sleep apnea. *Sleep Medicine* 14, 433-439.
55. Van Holsbeke, C., Verhulst, S. L., Vos, W., De Backer, J. W., Vinchurkar, S. C., Verdonck, P. R., van Doorn, J. W. D., Nadjmi, N. & De Backer, W. (2014) Change in upper airway geometry between upright and supine position during tidal nasal breathing. *Journal of Aerosol Medicine and Pulmonary Drug Delivery* 27(1), 51-57.
56. Van Holsbeke, C., Leemans, G., Vos, W. G., De Backer, J. W., Vinchurkar, S. C., Geldof, M., Verdonck, P. R., Parizel, P. M., Van Schil, P. E. & De Backer, W. (2014) Functional respiratory imaging as a tool to personalize respiratory treatment in patients with unilateral diaphragmatic paralysis. *Respiratory Care* 59(9), e127-e131.
57. Van Holsbeke, C., De Backer, J., Vos, W. & Marshall, J. (2018) Use of functional respiratory imaging to characterize the effect of inhalation profile and particle size on lung deposition of inhaled corticosteroid/long-acting  $\beta_2$ -agonists delivered via a pressurized metered-dose inhaler. *Therapeutic Advances in Respiratory Disease* 12, 1753466618760948.
58. Verhulst, S. L., De Backer, J., Van Gaal, L., De Backer, W. & Desager, K. (2008) Adenotonsillectomy as first-line treatment for sleep-disordered breathing in obese children. *American Journal of Respiratory Critical Care Medicine* 177(12), 1399.
59. Vermeulen, M., Claessens, T., Van Der Smissen, B., Van Holsbeke, C. S., De Backer, J. W., Van Ransbeeck, P. & Verdonck, P. (2013) Manufacturing of patient-specific optically accessible airway models by fused deposition modeling. *Rapid Prototyping Journal* 19(5), 312-318.
60. Vinchurkar, S., De Backer, L., Vos, W., Van Holsbeke, C., De Backer, J. & De Backer, W. (2012) A case series on lung deposition analysis of inhaled medication using functional imaging based computational fluid dynamics in asthmatic patients: effect of upper airway morphology and comparison with in vivo data. *Inhalation Toxicology* 24(2), 81-88.
61. Vos, W., De Backer, J., Devolder, A., Vanderveken, O., Verhulst, S., Salgado, R., Germonpre, P., Partoens, B., Wuyts, F., Parizel, P. & De Backer, W. (2007) Correlation between severity of sleep apnea and upper airway morphology based on advanced anatomical and functional imaging. *Journal of Biomechanics* 40, 2207-2213.
62. Vos, W. G., De Backer, W. A. & Verhulst, S. L. (2010) Correlation between the severity of sleep apnea and upper airway morphology in pediatric and adult patients. *Current Opinion in Allergy and Clinical Immunology* 10(1), 26-33.
63. Vos, W., De Backer, J., Gianluigi, P., De Volder, A., Ghys, L., Van Holsbeke, C., Vinchurkar, S., De Backer, L. & De Backer, W. (2013) Novel functional imaging of changes in small airways of patients treated with extrafine beclomethasone/formoterol. 86, 393-401.
64. Vos, W., Hajian, B., De Backer, J., Van Holsbeke, C., Vinchurkar, S., Claes, R., Hufkens, A., Parizel, P. M., De Backer, L. & De Backer, W. (2016) Functional respiratory imaging to assess the interaction between systemic roflumilast and inhaled ICS/LABA/LAMA. *International Journal of COPD* 11, 263-271.
65. Wu, X., Kim, G. H., Salisbury, M. L., Barber, D., Bartholmai, B. J., Brown, K. K., Conoscenti, C. S., De Backer, J., Flaherty, K. R., Gruden, J. F., Hoffman, E. A., Humphries, S. M., Jacob, J., Maher, T. M., Raghu, G., Richeldi, L., Ross, B. D., Schlenker-Herceg, R., Sverzellati, N., Wells, A. U., Martinez, F. J., Lynch, D. A., Goldin, J. & Walsh S. L. F. (2019) Computed tomographic biomarkers in idiopathic pulmonary fibrosis. *American Journal of Respiratory and Critical Care Medicine* 199(1), 12-21.



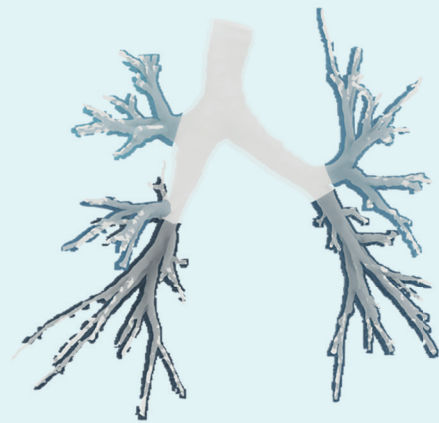
**LOBAR VOLUME**



**AIR TRAPPING**

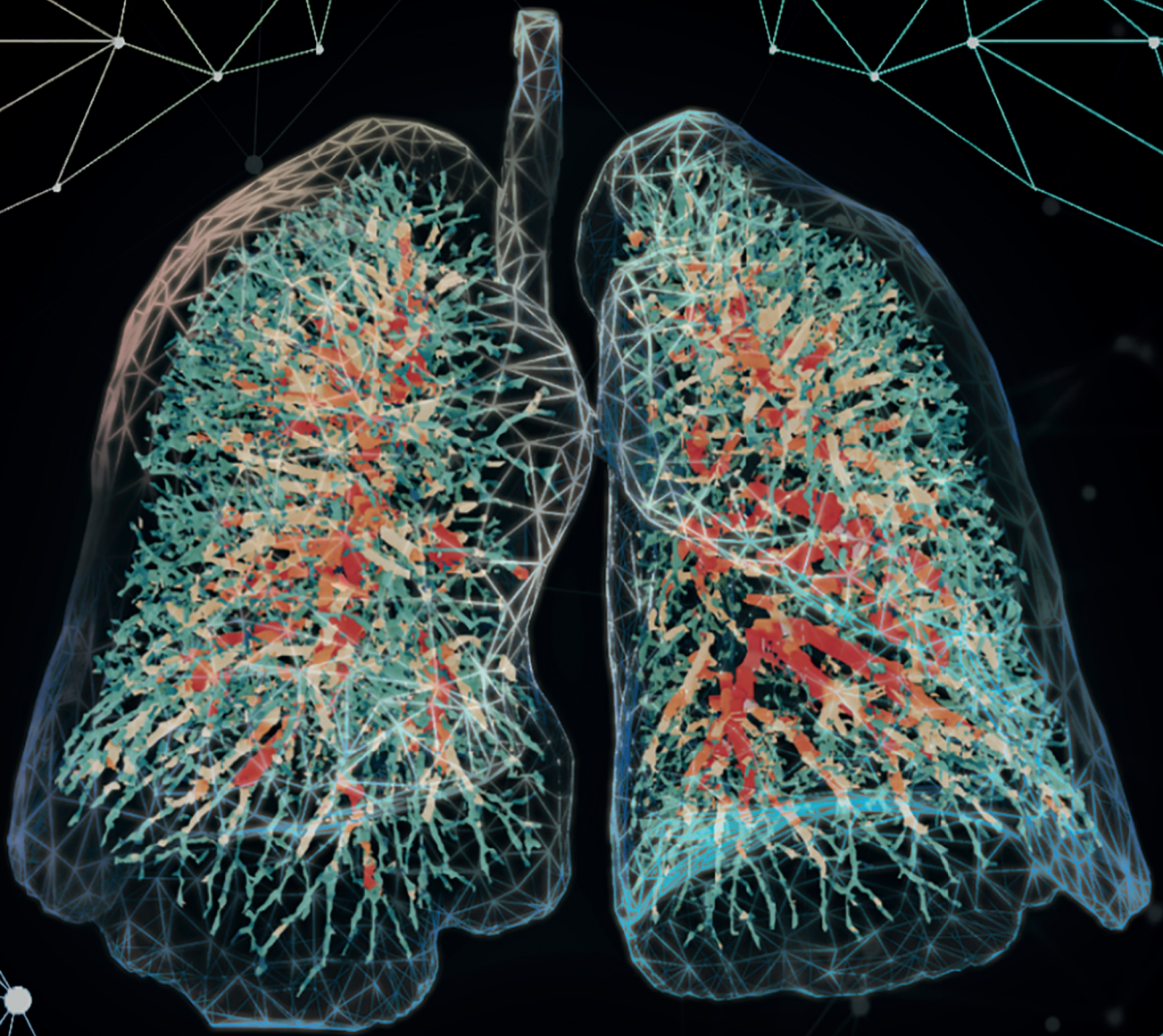

**EMPHYSEMA**



**AIRWAY WALL VOLUME**





**FLUIDDA**



Respiratory solutions  
for better patient care